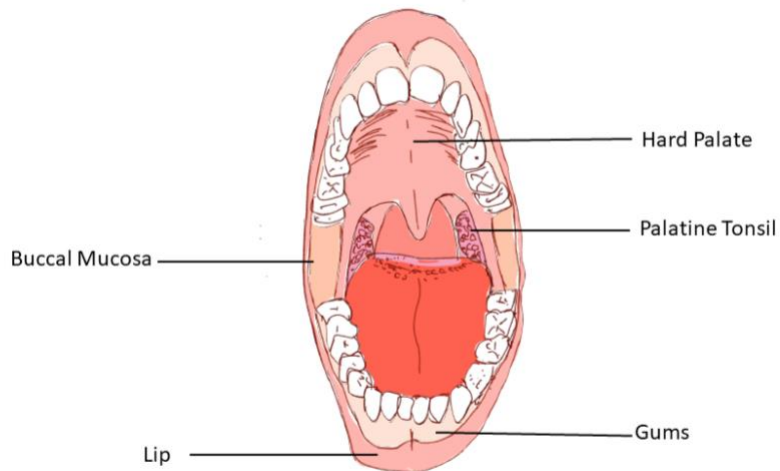
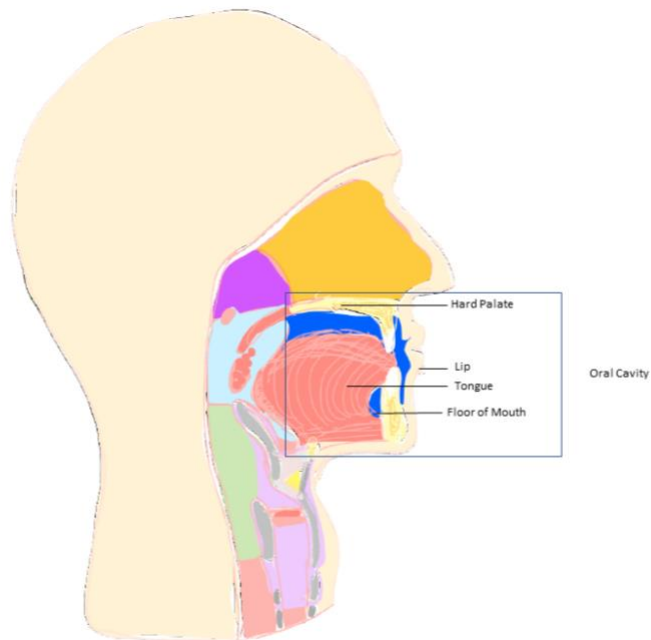


Oral cavity

a. Anatomy

- i. The oral cavity is the space between the lips anteriorly to the back end of the hard palate (bony roof of the mouth) and the circumvallate papillae (large taste buds that mark the boundary between the oral tongue and the base of tongue). The oral cavity includes the lips, gums, oral tongue, hard palate, buccal mucosa (inner lining of the cheek), and floor of the mouth.
- ii. The lining or mucosa of the oral cavity is composed of squamous cells. Squamous cell carcinoma is the most common type of oral cavity cancer, which develops when squamous cells transform into a cancer. Other types of oral cavity cancers also include minor salivary cancer which arise from the saliva-producing glands within the mouth.



b. Risk Factors

- i. Both tobacco and alcohol consumption are the main risk factors for development of oral squamous cell carcinoma
 1. The cancer risk is far greater with combined exposure to tobacco or alcohol, rather than either alone.
- ii. Smokeless tobacco has also been shown to increase the risk up to twofold
- iii. Chewing betel (areca nut) is a risk factor
 1. Most commonly seen in South Asia populations
- iv. Poor oral hygiene and ill-fitting dentures leading to mechanical trauma may contribute to precancerous lesions and cancer of the oral cavity

- c. Early symptoms of an oral cancer
 - i. Non-healing sore
 - ii. Growing mass inside the mouth
 - iii. White or red patch inside the mouth
 - iv. Bleeding inside the mouth
 - v. Oral pain
 - vi. Ear pain
 - vii. Trouble chewing or swallowing
 - viii. Loose teeth
 - ix. Difficulty or change in speech
- d. Diagnosis
 - i. Once a suspicious growth, ulcer or lesion is identified within the oral cavity, a biopsy of the suspected area will be required to confirm the diagnosis of an oral cavity mucosal malignancy. Very often the biopsy can be performed in the office using both topical and local anesthesia. Occasionally a loose tooth is an indication of an oral cavity gingival (gum) cancer, and biopsy will also include extraction of the associated tooth along with the mucosal gingival tissue. Brush biopsy or a superficial scraping of mucosal cells does not provide enough tissue and a formal biopsy will be necessary to establish a diagnosis. Further evaluation of the cancer will include a complete head and neck exam and possible in-office fiberoptic camera exam to assess the extent of the cancer within the mouth or evidence of a second malignancy within other areas of the head and neck.
 - ii. Your doctor may also order a variety of medical imaging including computerized tomogram imaging (CT scan), magnetic resonance imaging (MRI), positron emission tomography (PET) and dental imaging (cone beam scan or Panorex). These images will help to further delineate the extent of the cancer. Different types of imaging help to visualize different anatomic structures. For example, CT scans and dental imaging are particularly useful for visualizing the integrity of the jaw bones. Intravenous contrast enhanced CT scan and MRI can identify abnormalities in the mouth, jaw bone marrow or neck that suggest cancer spread. PET imaging is a special technology that identifies a glucose (sugar) molecule being absorbed by the cancer cells and help identify tumor in other parts of the body. Dental imaging also assesses the dental health in the event that radiation therapy is required.
 - iii. Human papillomavirus (HPV) testing is not indicated for oral cavity squamous cell cancers, because oral cavity cancers are rarely caused by HPV.
- e. Staging
 - i. The American Joint Committee on Cancer (AJCC) has created a staging system (TNM staging) to help guide treatment. The staging system groups cancers into stages based on their anatomic extent. The staging helps to determine the optimal treatment for a specific cancer, and provides information about expected survival rates.
 - ii. The staging system includes information about the extent of the original or local tumor (T classification or primary tumor extent), spread to lymph nodes (N-

classification or nodal metastases), and spread to distant parts of the body (M classification or distant metastases). Combinations of T, N and M-classifications produce an overall stage. There are four stages (Stage 1-4) reported with increasing disease burden and potentially worse survival as the AJCC overall stage number increases. In the oral cavity, factors that play a role in overall tumor stage include destruction of adjacent jaw bone; tumor thickness; appearance of the cancer cells under microscopic examination by the pathologist; and involvement of lymph nodes within the neck.

- iii. Lymph nodes are small oval shaped structures found within the fat of the neck that harbor specialized immune cells that filter and fight infection and disease. Cancer cells from the mouth detach from the cancer and can become trapped within the individual nodes. Once an oral cancer spreads to lymph nodes, it is considered more advanced, and is considered overall stage 3 or higher. In addition, the number of abnormal lymph nodes and their size is important. Sometimes, the cancer in a lymph node grows out of the lymph node, a property known as extranodal extension (ENE). A special subclassification for the lymph nodes is designed to report on the involvement cancer (number of nodes involved with cancer and size in centimeters within the lymph nodes of the neck, as well as ENE. This information affects a tumor's stage, and anticipated survival.

| Primary Tumor Stage: Oral Cavity | |
|----------------------------------|--|
| Stage | Description |
| TX | Primary tumor cannot be assessed |
| Tis | Carcinoma <i>in situ</i> |
| T1 | Tumor ≤ 2 cm, depth of invasion ≤ 5 mm |
| T2 | Tumor ≤ 2 cm, depth of invasion > 5 mm and < 10 mm; or , Tumor > 2 cm but ≤ 4 cm, depth of invasion ≤ 10 mm |
| T3 | Tumor > 4 cm; or , Tumor any size, depth of invasion > 10 mm and ≤ 20 mm |
| T4a | Extrinsic muscle of tongue involved, including extensive tumors with bilateral tongue involvement and/or depth of invasion > 20 mm |
| T4b | Very advanced local disease; tumor invades masticator space, pterygoid plates, skull base, and/or encases the internal carotid artery |

| Regional Nodal Stage: Oral Cavity | |
|-----------------------------------|---|
| N0 | No regional lymph node metastasis |
| N1 | Metastasis to a single ipsilateral lymph node ≤ 3 cm and ENE- |
| N2a | Metastasis to a single ipsilateral lymph node > 3 cm but not > 6 cm and ENE-; or , Single ipsilateral lymph node ≤ 3 cm and ENE+ |
| N2b | Metastasis to multiple ipsilateral lymph nodes ≤ 6 cm and ENE- |
| N2c | Metastasis to bilateral lymph nodes or contralateral lymph nodes ≤ 6 cm and ENE- |

| | |
|-----|---|
| N3a | Metastasis to any lymph node > 6 cm and ENE- |
| N3b | Metastasis to ipsilateral lymph node > 3 cm and ENE+; or , Multiple ipsilateral, bilateral, or contralateral lymph nodes and ENE+; or , Single contralateral node any size and ENE+ |

| AJCC Prognostic Stage Groups: Oral Cavity | |
|---|--|
| Stage | Description |
| 0 | TisN0M0 |
| I | T1N0M0 |
| II | T2N0M0 |
| III | T3N0M0, T1N1M0, T2N1M0, or T3N1M0 |
| IVA | T4aN0M0, T4aN1M0, T1N2M0, T2N2M0, T3N2M0, or T4aN2M0 |
| IVB | T4b, any N, and M0 |
| IVC | Any T, any N, and M1 |

f. Treatment

- i. The treatment of oral cavity cancers typically starts with surgery in which the primary tumor is removed along with the at risk or involved lymph nodes in the neck in a procedure called a neck dissection. Depending on the final pathology analysis, further therapy with radiation therapy or even chemoradiation therapy may be recommended to optimize chances of survival. In some patients with more favorable pathology findings, surgery alone without further added treatment is possible.
- ii. Some patients who undergo surgery for treatment of oral cavity cancers may also require a reconstructive procedure, usually performed at the same time as the cancer operation, to rebuild what is lost in removing the cancer. The purpose of reconstruction is to optimize speech and swallowing. Reconstruction can consist of a skin graft, a local flap from within the mouth rotated into the defect, or a free flap. A free flap consists of parts of tissue from the patient's own body that can be transplanted into the mouth to restore form and function that otherwise would be lost without reconstruction. This is a complex procedure that involves using techniques under the microscope to carefully reconnect the blood vessels of the tissue transplant to the recipient vessels in the neck to provide a successful reconstruction.

g. Survival

- i. Survival depends on how advanced the cancer is at diagnosis. The earlier the stage of the cancer, the higher the chance of survival. Delays in diagnosis and treatment may contribute to worse survival. But with aggressive therapy, even advanced oral cavity cancers that are stage IV are potentially curable.
- ii. Treatment of oral cavity cancer can have lasting side effects such as change in speech, change in diet, difficulty swallowing, dry mouth, neck scars, tissue stiffening, and change in how you look.

- iii. Side effects can especially be worsened if added therapy such as radiation is needed.
- iv. But with advances in reconstructive surgery for head and neck cancer, functional and cosmetic outcomes after surgery are continuing to improve.
- h. Surveillance/Survivorship
 - i. [Surveillance](#): As with any cancer, there is a risk that oral cavity cancer will come back ('recur') after treatment. 'Surveillance' means that your doctor(s) will monitor you after treatment with a combination of physical examination and imaging studies in order to detect disease that has recurred early. Some of these visits may be transitioned to a special survivorship clinic. Protocol details will vary from institution to institution. Surveillance typically lasts for at least 5 years. Once cleared by the treating physician, patients may transition into a cancer surveillance/survivorship clinic, often run by an advanced practice provider (APP) that is well trained in head and neck cancer surveillance.
 - 1. Physical examination: Your doctor(s) will examine you according to the following schedule:
 - a. Year One: every 1-3 months
 - b. Year Two: every 2-6 months
 - c. Years Three through 5: every 4-8 months
 - d. After 5 years: every 12 months or as needed
 - 2. Imaging: The timing and type of imaging you have will be based on your doctor's judgment and the initial tumor stage.
 - a. It is sometimes recommended to have baseline imaging within 6 months of completing treatment.
 - b. Imaging may include CT scans, PET/CT scans, MRI, or sometimes ultrasound.
 - c. Additional imaging will be based on your symptoms, exam, and your doctor's judgment.
 - d. It is important to let your doctor know if you feel a new persistent pain or neck mass.
 - ii. [Survivorship](#): Oral cavity cancer and its treatment can affect many areas of your health and quality of life. 'Survivorship' refers to caring for your health and well-being from the moment you receive your diagnosis, and for the rest of your life. Depending what your treatment involves, important parts of survivorship for oral cavity cancer may include:
 - 1. [Speech and swallowing evaluation and therapy](#): Speech-Language Pathologist, or SLP, with expertise in speech and swallowing for head and neck cancer patients may help you to retain or regain function lost as a result of your cancer or its treatment.
 - a. Swallowing: Safe swallowing is important for your health and quality of life. Poor swallowing function, called 'dysphagia', can lead to health problems such as pneumonia or malnutrition, and may lead to the need for a feeding tube for nutritional support.

You may also be referred to a dietician for guidance on how to maintain a nutritious diet even if you have dysphagia.

- b. Speech: Rehabilitation of your speaking is important for your communication and quality of life.
2. Oral and dental health: Oral cancer and its treatment can have a major impact on your teeth, taste, saliva and jaw bone health.
 - a. [Dental cleaning and care](#): Oral cancer patients should establish care early after diagnosis, ideally before treatment, with a dentist who has experience in head and neck cancer. Some dental work may be necessary prior to treatment. In the long term, patients should have routine cleaning and examination. Routine fluoride treatments may be recommended.
 - b. Radiation and dental health: In addition to the destructive effects of oral cavity cancer itself and surgery, radiation can be detrimental to your dental health. It is especially important for patients who undergo radiation to have regular dental care and excellent dental hygiene.
 - c. [Dry mouth](#): Dry mouth, or 'xerostomia', is common after radiation therapy and can have a significant negative impact on quality of life. There is no cure for xerostomia. If you have xerostomia, you can decrease the symptoms by staying hydrated, using salivary substitutes, and maintaining excellent dental hygiene.
 - d. [Osteoradionecrosis \(ORN\)](#): Patients who undergo radiation are at risk for breakdown of the jaw bone, or osteoradionecrosis (ORN). This may cause ulcerations, exposed bone, pain, and chronic infection. ORN is diagnosed with history, examination and imaging. Treatment may involve medications, hyperbaric oxygen treatments, or in advanced cases, bone removal and reconstruction.
 - e. Dental restoration: A prosthodontist with experience treating oral cancer patients may be able to restore lost dentition and fabricate obturators for defects of the palate. Ask your doctor for a referral to a prosthodontist if you are interested in learning about your dental restoration options.
 - f. Trismus: Surgery and radiation can cause difficulty opening your mouth, called trismus. This can interfere with dental care and with eating. Ask your doctor about ways to manage your trismus.
3. [Thyroid function testing](#): If you have had radiation therapy, you have an increased risk of low thyroid function, or 'hypothyroidism'. Symptoms of hypothyroidism may include fatigue, weight gain, constipation and depression. Your thyroid function should be tested every 6-12 months to determine whether you need treatment with thyroid hormone supplementation.
4. [Tobacco use](#):

- a. Most head and neck cancers are associated with tobacco use, especially smoking cigarettes.
 - b. Continued tobacco use after treatment is associated with worse survival and higher risk of other cancers, among many other negative health effects.
 - c. Quitting tobacco at any time will improve your overall health and chances of survival from head and neck cancer.
 - d. If you still use tobacco after head and neck cancer treatment, we strongly encourage you to consider quitting. Your doctor can help you find resources, including medications and counseling programs, that have been proven to help.
 5. Lymphedema: Lymphedema is swelling of the soft tissue that is common for patients who have had surgery and/or radiation. Specialized Physical Therapy called Lymphedema Therapy, including massage, compression garments, exercises and skin care, is available and can significantly improve lymphedema.
 6. Shoulder dysfunction: Many head and neck cancer survivors have shoulder dysfunction, including decreased range of motion, weakness and stiffness as a result of surgery and/or radiation. Physical therapy is very helpful in improving shoulder function. If you have problems with your shoulder, ask your doctor about a referral to a physical therapist.
 7. Obstructive sleep apnea: Survivors of head and neck cancer treatment are at risk for obstructive sleep apnea (OSA) because of changes to the upper airway anatomy. Symptoms may include daytime sleepiness, snoring, gasping or choking during sleep, daytime headaches, and irritability. OSA is diagnosed with a sleep study, and there are several options for treatment. Discuss your risk of OSA with your doctor.
 8. Carotid artery stenosis evaluation: Radiation therapy to the neck increases the risk of carotid artery narrowing (stenosis) later in life. Carotid artery stenosis increases the risk of stroke. If you have had radiation to your neck, ask your doctor about an ultrasound or carotid doppler study to look for carotid artery stenosis.
 9. Mental and sexual health: Head and neck cancer and its treatment can result in cognitive dysfunction, anxiety, depression, body image concerns, and changes in sexual function and desire. If you suffer from any of these, you are not alone. Ask your doctor about meeting with a mental health professional to determine whether counseling and/or medication may be helpful for you.
 10. Hearing evaluation: Head and neck cancer treatments, especially with certain chemotherapy drugs, can cause hearing loss. If you have decreased hearing, you should have a hearing test to evaluate your hearing and determine whether you may benefit from hearing augmentation, such as with a hearing aid.
- i. Questions for your doctor

i. Before/during treatment:

1. What types of treatment are recommended (such as surgery, radiation, and/or chemotherapy)?
2. Are there any other treatment options that I should learn about, such as clinical trials?
3. Should I see a dentist before treatment begins?
4. How long will treatment take? How long will it take to fully recover after treatment?
5. What are the risks and side effects of each part of treatment? Which side effects are temporary, and which might be permanent?
6. Will I need a feeding tube or a breathing tube (tracheostomy)? Will they be temporary or permanent?
7. What will my swallowing, speech and breathing be like after treatment?
8. Will I have any other functional problems after treatment?
9. Will I be able to keep doing my job after I've recovered?

ii. After treatment:

1. Should I have any imaging studies?
2. When should my next follow-up appointment be, and with whom?
3. Should I have my thyroid function tested?
4. Should I be referred to a speech and language pathologist (SLP), and or to a physical or occupational therapist?
5. Am I receiving appropriate dental care?
6. Are there any options for dental rehabilitation for me?
7. Should I have a sleep study?
8. Do I need a carotid artery ultrasound?
9. Should I have a hearing test?